

# Case Study: *Esthetic & Biologic Management of Diastema Closures Using Porcelain-Bonded Restorations for Excellent & Predictable Results*



by Lynn A. Jones, D.D.S.

*Dr. Lynn Jones received her D.D.S. from the University of Washington and is now recognized for both her cosmetic dentistry and innovative management practices. She is an Accredited Member of the American Academy of Cosmetic Dentistry, has served on the board of directors and is currently an Accreditation Examiner. Dr. Jones has spoken on Micro dentistry at the AACD, WSDA, and other meetings. She is the director of "Aesthetics Continuum" for the University of Washington's CDE program focusing on cosmetic and reconstructive dentistry. Dr. Jones maintains a private practice in Bellevue, Washington.*



by Michelle Y. Robinson

*Michelle Robinson specializes in esthetic and reconstructive cases fabricated from a full range of restorative materials. An active General Member of the American Academy of Cosmetic Dentistry, her goal is to help develop new materials to solve esthetic and reconstructive needs. As a clinical instructor for Team Aesthetic Seminars, she has gained a great deal of experience teaching clinical programs with Dr. David Hornbrook and Dr. Thomas Trinkner. Her desire is to share her knowledge with students and help propel them forward in their quest for excellence.*

## DOCTOR'S PERSPECTIVE

### INTRODUCTION

One of the clearest indications for porcelain-bonded restorations is diastema closures. Veneers can make a dramatic improvement to the appearance in the smile with undersized teeth in an oversized arch (Figs 1 & 2). Before we had the ability to bond porcelain veneers to the teeth, these types of cases were practically untreatable. Although the occlusion often is ideal in diastema cases, the teeth are too small for the size of the jaw. Orthodontics can only rearrange the spaces. Composites might work but would be less predictable in large cantilevered spaces between worn teeth, and composite is more difficult to control where deep subgingival margins are necessary for esthetic emergence profiles between the teeth. The other option, porcelain crowns, would have required excessive reduction of otherwise healthy teeth, and with dubious esthetic results.

Well-controlled bonded porcelain restorations can produce beautiful results while preserving the strength of the original tooth. If the guidelines for good smile design and tooth preparation are combined with occlusal management, veneers can look, feel, and function like healthy natural teeth.

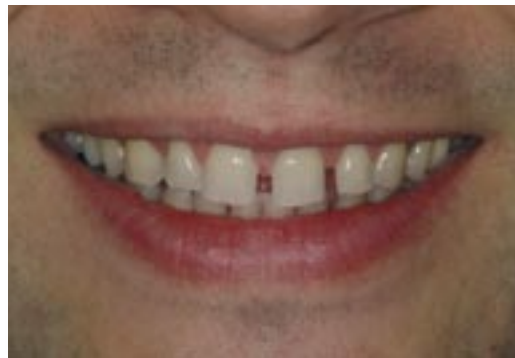A smile with a high lip line and large spaces poses some special challenges. Careful attention to the details of interproximal emergence profiles, biologic width, and papillary height is necessary to get excellent results. If the teeth are worn or if the spaces are wide, the teeth will appear to be disproportionately



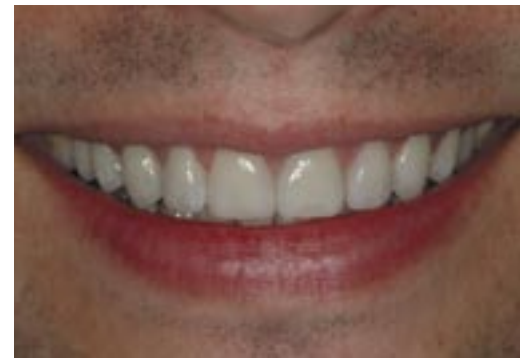*Figure 1: Pretreatment diastema undersized teeth relative to the size of the arch.*



*Figure 2: Veneers can make a dramatic improvement to the appearance.*



*Figure 3: Pretreatment smile.*



*Figure 4: Posttreatment smile.*

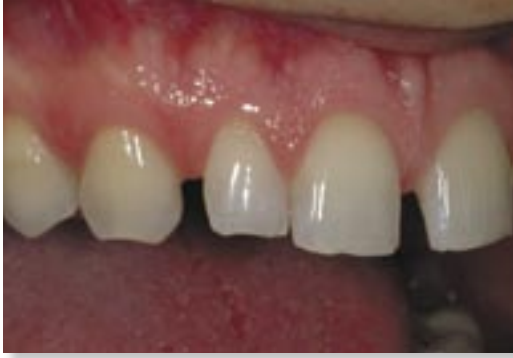short and wide after the diastemas have been closed with restorations. The apparent height-to-width ratios can be managed to some degree by artistically controlling reflective and defective surfaces. It also is possible to increase the actual length of the tooth a limited degree by extending it gingivally when combined with a crown-lengthening procedure, and incisally until it interferes with the envelope of function. In extreme cases the entire vertical dimension of occlusion may need to be altered to achieve the desired length.

The mesiodistal tooth position itself is another consideration, especially in a case where there is a high lip line. If the spaces are not sym-

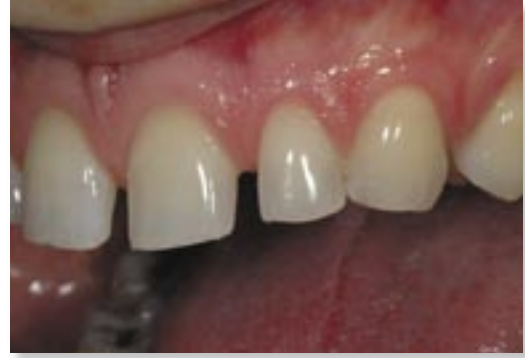metrical or the apex of the gingival scallop is out of alignment because a tooth is out of position, it can make it impossible to achieve the correct gingival architecture. In an esthetically sensitive patient, even a slightly asymmetrical papilla can be a concern. With proper planning and understanding of the biologic and esthetic rules of soft tissue management, these issues can be predicted and controlled. The purpose of this article is to use a case study to show how to overcome these obstacles with careful planning, soft tissue management, attention to occlusion, preparation design, laboratory communications, and excellent porcelain work.

## **PATIENT'S CONCERNS**

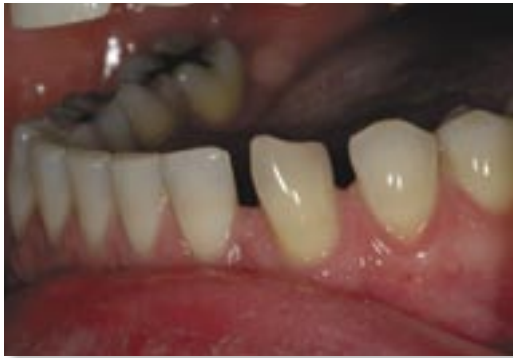The patient wanted to close the spaces between his teeth (Figs 3 & 4); he wanted very white teeth with no unsightly amalgam restorations; and he did not like his flat, worn canines (Figs 5 & 6). He is an esthetically sensitive patient with a high lip line. The spaces on the lower left were almost as much of a concern to him as the spaces in the upper anterior (Figs 7 & 8). He also was somewhat concerned about the worn incisal edges. He had consulted with an orthodontist, who had advised him that his teeth were too small to completely close the spaces with tooth movement.



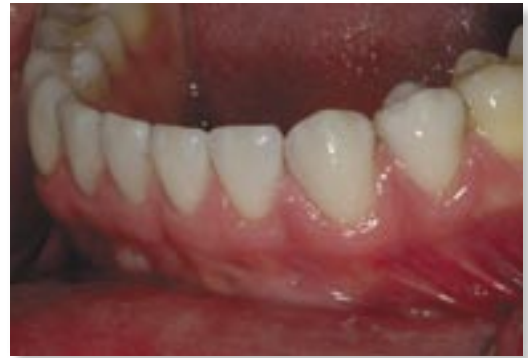*Figure 5: Pretreatment maxillary right lateral.*



*Figure 6: Pretreatment maxillary left lateral.*



*Figure 7: Pretreatment mandibular left lateral.*



*Figure 8: Posttreatment lower left.*

## DIAGNOSIS AND TREATMENT PLAN

The patient's medical history was noncontributory. He is 42 years old and has a healthy dentition with no caries and good periodontal health; there are preexisting amalgam restorations on ## 2, 3, 4, 18, 29, and 31; and preexisting composite on ## 14 and 15. Teeth 13 and 19 have preexisting endodontic treatment and crowns. All four wisdom teeth are missing. Moderate wear was noted on the anterior teeth. Diastemas ranging from 0.5 to 2.5 mm are located between almost every tooth anterior to the first bicuspid. There are no signs of temporomandibular disorder (TMD) and the occlusion is Class I normal with large diastemas

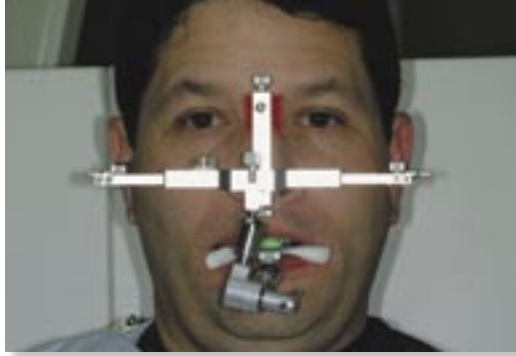To achieve the desired results, the teeth would be whitened first with an in-office whitening system. All of the conservative Class I amalgam fillings would be replaced with direct composite. Teeth 4–13 and 21–28 would be restored with reverse 3/4 porcelain-bonded restorations.

There are various methods for developing the smile design, including full intraoral mock-ups done directly on the teeth, or mock-up of the maxillary central incisors only and then doing the diagnostic wax-up. To design the smile for this case I chose to use computer imaging and laboratory-made wax-ups.

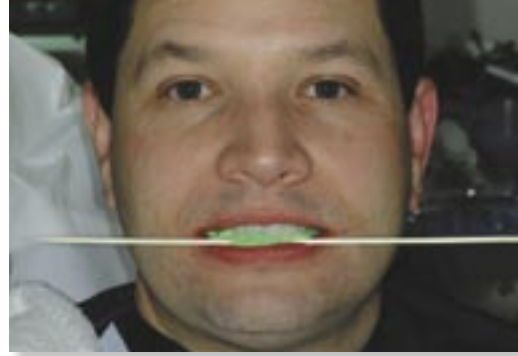The original smile design was developed with computer imaging using the Image/FX program from

Sci-Can (Pittsburgh, PA). Three different designs of varying lengths were presented to the patient to gauge his expectations and clarify his esthetic desires. It helped to determine whether we should design a flat smile or one with more contours; and how long he wanted his teeth. From the imaging, the patient immediately rejected longer teeth and expressed a desire for pointed canines. He also agreed that wider incisal embrasures looked better.

Once a smile design is selected from the image, the necessary records are made for a preliminary wax-up. The laboratory will need specific information to give the best result. If the occlusion is going to be equilibrated, this is the easiest time to do it. In this case the equilibration was



*Figure 9: Facebow.*



*Figure 10: A level stick-bite.*

not indicated, so the bite registration was made in centric occlusion. A level facebow was made for the Artex articulator (Girrbach Dental; Pforzheim, Germany), a level stick-bite was made, and both recordings were confirmed with photographs (Figs 9 & 10). A “before” smiling photograph and the selected image were included with written instructions for the desired overbite and overjet and desired tooth length (computer photos are not 1:1).

### **DETERMINING THE DESIRED POSITION OF THE INTERPROXIMAL CONTACT**

On the preparation day after the patient has been anesthetized, the interproximal depths are sounded to determine this specific patient’s biologic width of tissue and how deep the margin can be placed to establish the proper emergence profile. This also helps determine the point where the proximal contact should meet. A biologic width of 2.5 mm or more is necessary to prevent a violation that causes chronically red and inflamed gingiva. To create the desired emergence, the margin must be placed as far below the tissue as possible. In most cases, 1 to 1.5 mm is ideal for controlling the black holes and avoiding the periodontal

biologic width. Note that the inter-radicular distance can influence the distance between the interproximal contact and the alveolar crest. A depth of 5 mm or less is necessary to guarantee that the papilla will fully occupy the gingival embrasure space<sup>1</sup> based on roots that are 2.5 mm apart. In this case, the sounding depth between teeth 8 and 9 was 4 mm and the interradicular distance was 3.5 mm. That meant the contact point should be no more than 4 mm from the alveolar crest.

For example, if the sounding depth were 3 mm, space closure would be more difficult because this patient has a naturally narrow biologic width. That means the contact point would be moved to within 3 mm of the osseous crest; if it were placed 4 mm above the alveolar crest it would result in a black triangle. A sounding depth of 5 mm may mean that there is a long epithelial attachment. Placing a deep margin may result in recession and loss of papilla. If the contact point is made at 5 mm, in this example, it is likely to leave a black hole. So it is still a good idea to make the contact 4 mm from the alveolus.<sup>2</sup>

Very wide diastemas over 4 mm require an extreme alteration of emergence profile approaching 90°. This causes an unnatural gingival

contour and a very boxy looking tooth. If the gumline recedes to reveal the margin of the veneer with its obvious overhang, the esthetics will be ruined. If that is the case, it would be preferable to rearrange the spaces with orthodontics so that they are distributed evenly between all of the anterior teeth prior to veneering. Evaluate the shape of the teeth and the size of the spaces. If the coronal portion of the tooth is not much wider than the root (as we see in this case) and the spaces between the teeth are under 3 mm, the contours of the crown should appear to be normal.

### **GINGIVAL APEX**

Gingival contours are distorted when the tooth is made wider to close a space. The apex of the gingival margin will not move even if you perform a crown-lengthening procedure.<sup>3</sup> The apex will always be over the root prominence. If this is not acceptable then the tooth will have to be moved by orthodontics.

In this particular case, #8 is tilted to the distal but the gingival apex of the crown is very close to the proper position (Fig 11). This made it possible to veneer the tooth without orthodontically repositioning it (Fig 12). Had #8 been in the same

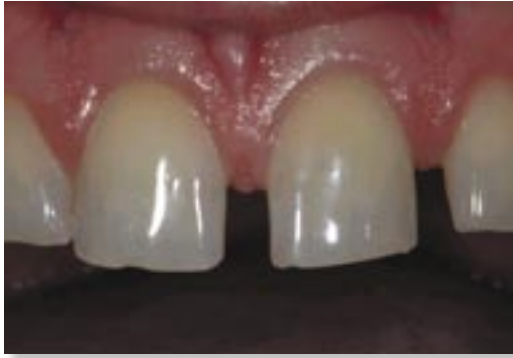

Figure 11: Pretreatment retracted anteriors.

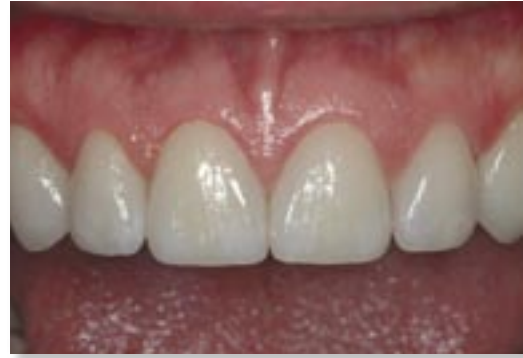

Figure 12: Posttreatment retracted anteriors.

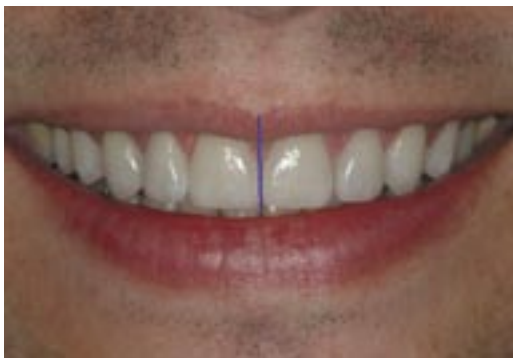

Figure 13: Midline placement.




Figure 14: The teeth can be made to look narrower by decreasing the area of the reflective surface.

position with the root vertically above it, the apex of the gingival scallop would have been in the wrong place and the midline papilla would have been asymmetrical. In that case, minor tooth movement or repositioning the dental midline with porcelain to compensate for the asymmetry would be required.

### GUM LIFTS

Another way to control the emergence profile and create a more desirable height-to-width ratio is to do a gum lift. A gum lift by either a gingivectomy alone or combined with osseous recontouring of the facial surface has become an essential adjunct to many cosmetic-

veneering procedures. About 80 percent of the population have some gingival display. The transition from the tooth to the gingiva poses one of the most challenging cosmetic problems when closing diastemas. A gum lift serves a dual purpose: it improves the height-to-width ratio of a short, wide tooth; and it helps to lengthen the taper of the gingival scallop around the necks of square-looking teeth.

A gingivectomy gives a longer run at the interproximal emergence profile so the gingival contours look smoother and more tapered rather than coming out at a right angle to the proximal wall of the tooth. The goal is to increase the scallop, where

the osseous and gingival architecture around widely spaced teeth tend to be flat.

### MIDLINE AND GOLDEN PROPORTION

#### MIDLINE

A line connecting the lowest point of the V in the upper lip with the midline of the lower incisors defines the midline (Fig 13).<sup>4</sup> Locating the midline varies from one case to the next and sometimes, for various reasons, we choose to ignore it. More important than the location of the midline is the degree of cant. Variance in the mesiodistal position of the midline is not usually notice-




Figure 15: The teeth can be made to look smaller and narrower by tapering the incisal angles toward the tooth and the opening of the embrasure.

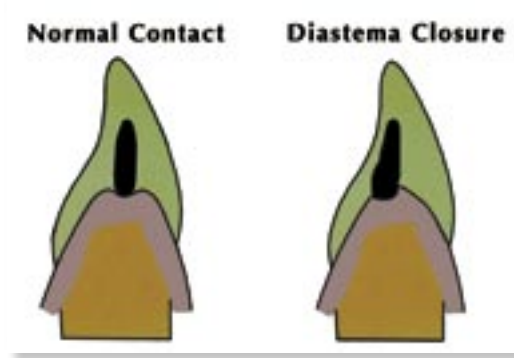


Figure 16: Placement of the interproximal contact.

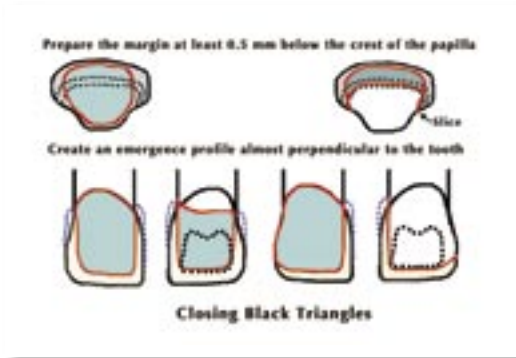


Figure 17: Closing black holes/emergence profile.

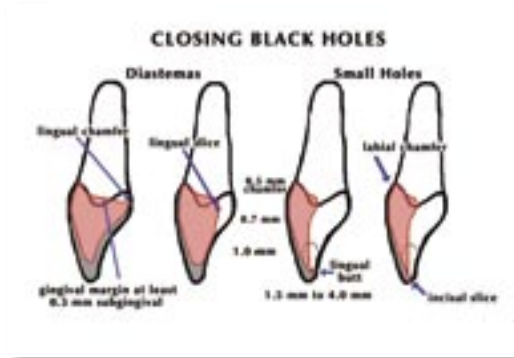


Figure 18: Closing black holes/margin placement.

able. A midline cant, however, generally is the most visible distraction from the esthetics of an otherwise normal healthy smile.<sup>4</sup>

To obtain a record of the vertical midline, a facebow for an Artex articulator was made over the prototype restorations (Fig 9). Before the facebow recording was set the patient was asked to stand straight. The earbow has a little play inside the ear and the universal joint, which connects it to the bite-fork, moves freely. The earbow is attached to the bite-fork, which is securely positioned on the teeth with a maxillary bite registration so that it remains stationary. While the patient was standing with his head level, the front of the earbow was maneuvered into a line parallel with the floor. This position was confirmed with a level on the

earbow and a photograph to confirm the relationship of the earbow to the face. Several reference points have been suggested to determine the true vertical in the patient's face. Different elements come into play, depending upon the patient. The interpupillary line is perhaps the most frequently used reference but it has drawbacks because the eyes often are not level. It also has been suggested that a line connecting the exact center of the bridge of the nose and the center of the labial filtrum represents the best vertical line; another suggestion is to use the horizon or a level to determine true vertical in the smile. Like many artistic decisions, judgment will guide which of these guidelines is most useful in an individual case. In this particular case the patient's face was very symmetrical and all

of these guidelines indicated the same vertical line. A stick-bite with a photograph is used to confirm the facebow recording and give the laboratory another point of reference for ensuring a vertical midline. With these two pieces of information, the laboratory is able to mount the case on an articulator with the occlusal plane and smile line oriented in the right plane. The stick-bite is made over the final prototype restorations to give the horizontal orientation of the smile line and also to indicate the incisal edge position of the provisional restorations (Fig 10). The stick-bite is made by spinning a stick (a disposable paintbrush works) into the soft registration material at the incisal edge of the upper centrals while the patient bites in centric occlusion.

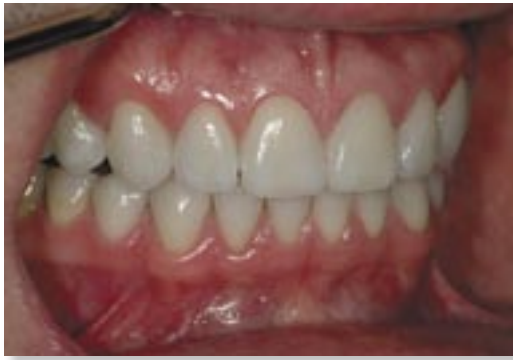

Figure 19: Posttreatment retracted right lateral.

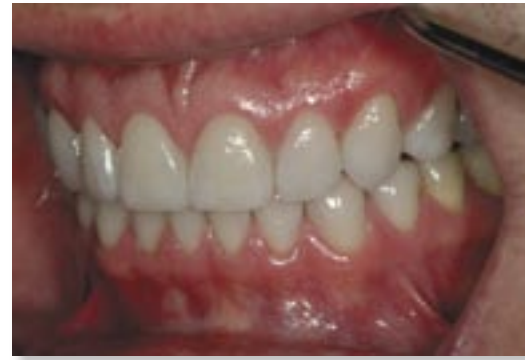

Figure 20: Posttreatment retracted left lateral.

### GOLDEN PROPORTION

The ratio of the centrals to the laterals in this case is 1:6.9, or very close to Golden Proportion. The ratio of the laterals to the canines is 1:0.88—a little further from Golden Proportion but not enough to be a distraction from the harmony of the smile design. The ratio of the canines to the first premolar is 1:0.75, once again close to Golden Proportion. The importance of Golden Proportion has been much debated and has been demonstrated to be the exception more often than the rule.<sup>5</sup> It is helpful to use as a guide if something doesn't look right, but very few anterior teeth are arranged exactly in Golden Proportion.

More important than Golden Proportion is the symmetry of the teeth and harmony with the face and smile. The facial of 6 and the distal of 8 and 10 were out of alignment (Fig 3). To achieve symmetry, those surfaces were contoured to be parallel with the distal contours of the remaining teeth prior to preparing the teeth for porcelain.

### CONTROLLING ILLUSIONS

*Are these rectangles the same size? They illustrate the next principle in illusions for creating esthetic space closures (Fig 14).*

The apparent size of the tooth is identified primarily by the reflective surface, that is, the surface that reflects light back into the eye of the viewer. It does this because that surface is perpendicular to the line of sight and directs the light straight back to the viewer and appears brighter. The deflective surfaces direct the light away from the viewer's eye and cause that part of the surface area to recede. In this case the actual height-to-width ratio is 1.0:0.9 on the centrals, but the reflective surfaces are 1.0:0.7. Controlling the light this way makes these central incisors appear narrower than they actually are, just like the rectangle on the right in the previous illustration. Yet both rectangles are exactly the same size.

Another way to make the rectangle look narrower is to physically take parts away. Rounded incisal angles create an optical illusion that causes the tooth to appear narrower by drawing the eye toward the center of the tooth. Also, the tooth is actually narrower in the incisal region, which helps to reduce excessive bulkiness. To make the tooth look narrower, the incisal edge has been tapered in to a ratio of 0.7:1.0, similar to the rectangle in the illustration (Fig 15).

### PREPARING THE TEETH

To esthetically close a diastema, the interproximal contact is placed more to the lingual (Fig 16). By moving it lingually it creates a larger embrasure. This is how the greater deflective surface areas are created, thus making the reflective surfaces appear narrower. This technique is also useful in giving the teeth more relief if the esthetics appear flat and lifeless.

Another problem with diastemas is that the papillae are usually flat. This leads to the dual challenge of creating a pointed papilla and completely closing the little black holes in the gingival embrasure (Fig 17). If the contact is extended gingivally and toward the lingual it can be used to create volume with the porcelain, which will then push the papilla forward and incisally into the gingival embrasure on the facial of the contact. This will help to prevent little black holes in the gingival embrasure and make the papillae look longer and more pointed.

If the sounding depth is only 3 mm, the margin cannot be placed more than 0.5 mm below the tissue. A deeper margin could potentially violate the biologic width of the periodontium. In a case like this, the emergence profile would have to be almost perpendicular to the

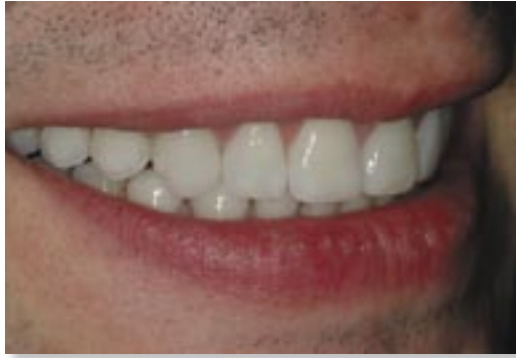

Figure 21: Posttreatment right lateral view.

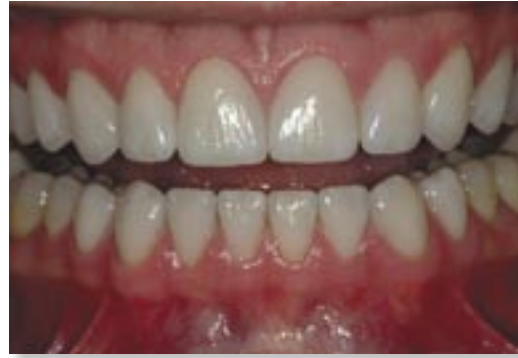

Figure 22: Posttreatment retracted anteriors.

interproximal wall of the tooth and the contact would have to be very long. This is easier to do with circumferential veneer but a reverse 3/4-veneer design works if the margins are placed well to the lingual of the contact area (Fig 18).

*The margin of the veneer must be placed apical and lingual to the papilla, as shown in Figure 16.*

The apparent contact area should be about 50 percent of the full length of the central incisor. The preparation design for d.SIGN<sup>®</sup> (Ivoclar/Vivadent; Amherst, NY) porcelain should allow a thickness of 0.5 mm at the gingival margin, 0.7 mm in the mid-body and at least 1 mm in the incisal third to prevent dentin shine-through and to conceal the silhouette of the preparation under the porcelain.

If the margin is placed too far to the labial several problems occur. First, the laboratory technician will not have enough room to create a deep labial embrasure and large deflective surfaces to visually narrow the tooth. Second, the margin of the porcelain will protrude from the gingival-axial wall, creating a plaque trap. The emergence profile from the gingival margin must be almost 90° and near the labial surface, causing an unnatural gingival con-

tour—and the technician still might not be able to completely close the little black hole.

Combining all of the elements of planning the diastema closure smile design, correct preparation design, proper margin placement, adequate tooth reduction, beautiful porcelain contours, color, and surface texture, we were able to achieve the excellent results illustrated in this article (Figs 19-22).

#### References

1. D Tarnow, AW Magner, P Fletcher. The effect of distance from the contact point to the crest of bone on the presence or absence of the interproximal dental papilla. *J Periodontol* 63(12):995-996, 1992.
2. JC Kois, RT Vakay. Relationship of the periodontium to impression procedures. *Compendium*, 21(8):684-692, 2000.
3. C Townsend, Resective surgery: An esthetic application. *Quintessence Int* 24(8):535-542, 1993.
4. VO Kokich Jr., HA Kiyak, PA. Shapiro. Comparing the perception of dentists and lay people to altered dental esthetics. *J Esthet Dent* 11(6):311-324, 1999.
5. JD Preston, The Golden Proportion revisited. *J Esthet Dent* 5(6):247-251, 1993.

## LAB TECHNICIAN'S PERSPECTIVE

### INTRODUCTION

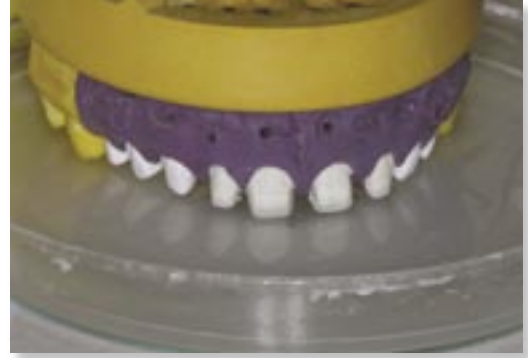Diastema cases present many esthetic challenges. One of the challenges for the ceramist in this situation comes when the restorations appear too wide or out of proportion (ideal is 75 percent width-to-length ratio on centrals). We are able to control what appears to be the width of the tooth by exaggerating the deflective areas and minimizing the reflective area (facial) of the tooth/teeth. To do this, the contacts must be moved to the lingual of the interproximal surface and the embrasures must be opened to allow for light illumination. If the embrasures are not opened enough the tooth/teeth will look "square" or "boxy" and the food will trap near the papilla, resulting inevitably in unhealthy tissue. After moving the contacts lingually and filling the "black triangle" spaces with porcelain, we sometimes are left with small cantilever pontics that appear to be part of the tooth. These ledges are easily maintained if constructed properly.

Upon laboratory receipt of the case, the communication letter is

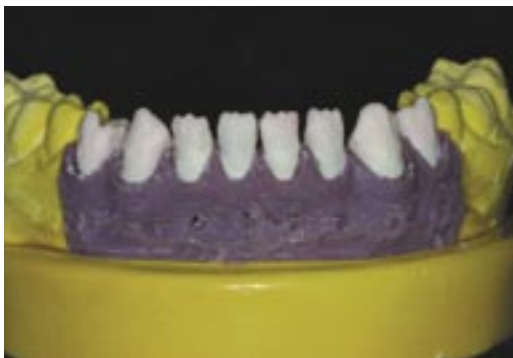



*Figure 23: Incisal matrix made from putty for incisal edge position.*



*Figure 24: Soaking of refractory dies prior to porcelain application.*



*Figure 25: Application of undiluted dentin in lobe formation to create base structure.*



*Figure 26: Fired refractory dies.*

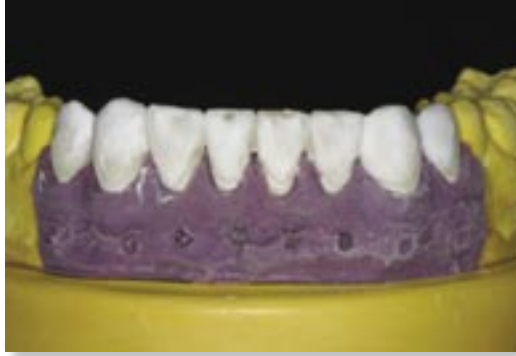read and the case is logged in, while ensuring that all items needed to complete the case as requested are included. All items that need to be disinfected are processed according to OSHA requirements. The case is then sent to the model department for the impressions to be worked up. Before the stone models are trimmed, the accuracy of the stick-bite is verified with the included photos. The maxillary model is trimmed with the stick-bite on the anterior teeth, ensuring that the base of the model will be parallel to the maxillary plane. The maxillary model is trimmed to the mandibular. All other models are trimmed in a similar fashion, resulting in parallel bases on all models. One prepped model is pinned and all

models are based using the split-cast system. The pinned models are sectioned into individual dies, but before the dies are replaced in the base, the adjacent pinned teeth and all bases are polished. All models are mounted, cross-mounted, and polished again. The ceramist reviews the case and the doctor's requests. Refractory work is then done. *The success of any refractory case depends heavily upon the level of refractory work your lab team is capable of creating.* Refractory die position is verified by an incisal matrix made from a solid model. Rotation or misplacement of any die will be detected and/or corrected at this time.

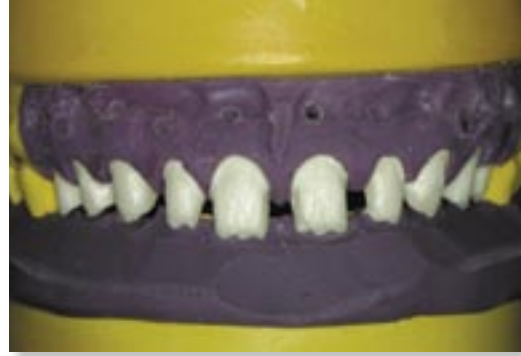## **PORCELAIN WORK BUILT IN d.SIGN PORCELAIN**

When reviewing a diastema case, there are several things that need to be addressed before starting porcelain application:

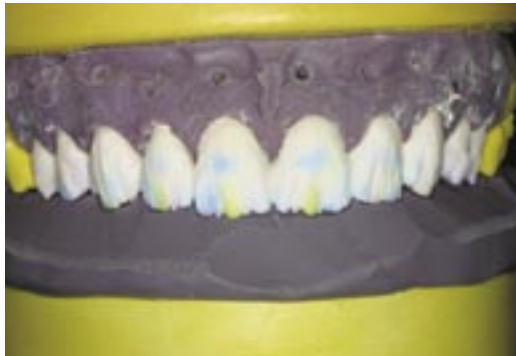- Where have the contacts been placed in the provisionals?
- Are there "black triangles" present?
- Has the doctor prepped slightly subgingival to allow for triangle closure?
- How wide are the teeth to be built?
- What is the final desired length?
- Are the Golden Proportions pleasing to the eye?



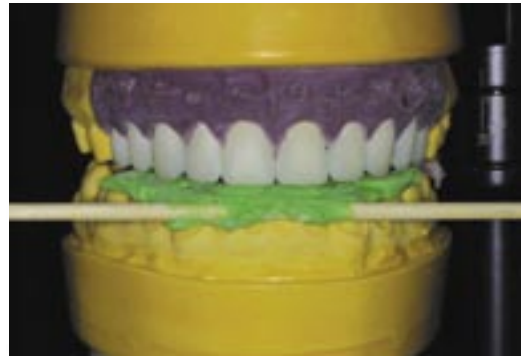*Figure 27: Full contour build-up.*



*Figure 28: Creation of internal lobes using the incisal edge matrix for correct placement.*



*Figure 29: Layering of different internal effects.*



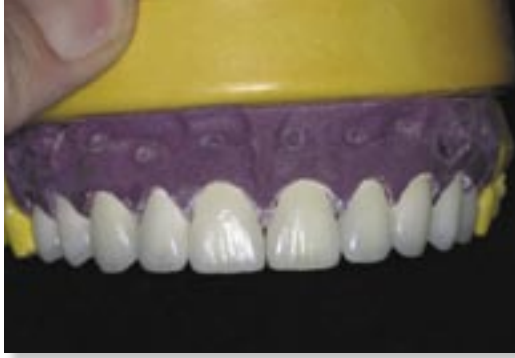*Figure 30: Verification of the horizontal plane of the restorations.*

This is where the provisional restorations come into play. Models of provisional restorations (as well as photos of them) are necessary when building a diastema case. They answer all of the above questions and provide a 3D visual to work from.

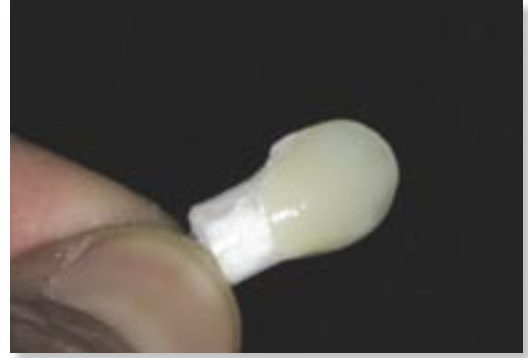By placing the maxillary provisional model on the articulator with the mandibular model, it is possible to make an incisal edge matrix of the maxillary against the mandibular model (Fig 23), thus providing the incisal edge position, tooth width, and final veneer length. Again, the ceramist's artistry can enhance what has already been established. Provisionals take the guesswork out

of almost any case. What color(s) are the prepared teeth (i.e., Is there any masking that needs to be done to achieve the final desired color of a B-1)? Luckily, the prep shades in this case are ideal, which leaves many options. Should the upper or the lower be built first? Should they be built simultaneously, as the preps are opposing each other? It is best to try to choose the simpler way to avoid problems. The choice here is to build the lower restorations to full contour (pre-glaze) before starting the upper units. I build in several layers and fire many times to have the most control over the final result. By carefully planning the building strategy it is easier to avoid making internal mistakes.

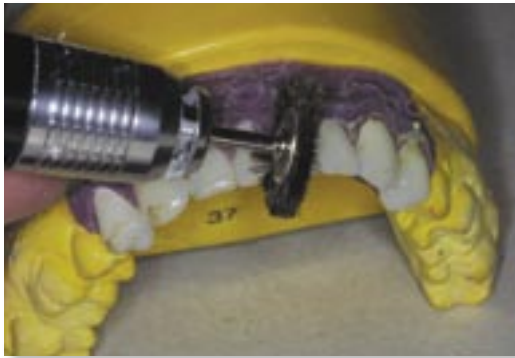The refractory dies are soaked in water prior to any porcelain application (Fig 24). Neutral or clear porcelain is applied in a small crescent moon area at the margin. This will allow the restorations to blend well with the natural dentition when seated. Undiluted dentin shade is placed over the rest of the prepped areas, with lobe formations extending over the edges of the preps (Fig 25). The dies are then fired (Fig 26). The dies are cooled, soaked again in water, and placed back into the water reservoir matrix. A dentin/neutral mix is applied as a full contour in the gingival half and as full contour lobing (using the upper provisional model as a guide) on the incisal half. The dies are fired



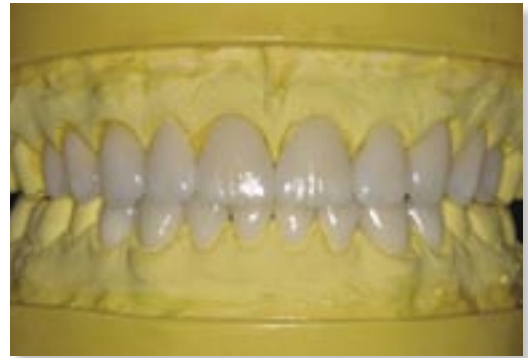*Figure 31: Restorations prior to final polish and devesting.*



*Figure 32: Porcelain added to embrasure area to correct a potential "black triangle."*



*Figure 33: Final polish with a soft brush and porcelain polishing paste.*



*Figure 34: Completed restorations on solid model.*

again. Satisfied that the developmental lobe placements are correct, it is now time to build in internal effects. Effects are not created from surface staining. E3/E4 mix (Ivoclar/Vivadent; Amherst, NY) is placed on the mesial, distal, and middle lobes, extending slightly beyond the fired dentin in a finger-type effect. A yellow-gray finger is placed slightly off-center on the middle lobe for additional characterization. An E3 high-value band is added horizontally between the gingival and middle thirds and a khaki is applied sparingly (because the desired final shade is so light) on the cervical neck area. Before firing, the final internal touch is added in an almost "watercolor" fashion using a watery

variegation of salmon and light mammelon porcelains. These are difficult to apply but add greatly to the final beauty. A very wet liner brush with a heavily diluted mammelon effect is dragged down the incisal surface of wet porcelain. The dies are then fired again. Shade is constantly monitored between each firing. It is important to note that up to this point the contacts between each tooth are either open or loose. It is easy to overbuild, resulting in mispositioning a die if the contacts are binding. When these are placed back into the reservoir matrix the effects are evaluated; these can be sharpened with a mini-diamond disk if any of them appear to run together. Next, teeth are built to

full contour with diluted dentin in deficient areas on gingival half and a variegated E1, E2, and TS1 across the incisal edge (Fig 27). The dies are fired again. After checking contacts and occlusion, the contours are finalized. Surface morphology is emphasized. If any add-ons are needed, they are applied with either an E2 or neutral, depending upon the area.

Moving onto the maxillary arch, the units are built in a similar fashion. Contacts are built to the lingual, and the deflective angles of the teeth are broader to make each tooth look narrower. The key here is to keep the transition between the reflective and deflective angle smooth

to avoid harsh light reflection that results in an unnatural look. The incisal matrix made from the provisional restorations is used as a guide to determine where to build the lobes and (of course) tooth width and length (Fig 28). When building the maxillary units the same steps are followed, with the exception of heavier internal effects with more incisal porcelains to create more incisal characteristics (Fig 29). The stick-bite is clipped onto the lower model to be used as a guide for a correct horizontal plane as well as a perpendicular midline (Fig 30). Periodically during the incisal porcelain application all excursive movements are checked against the lower units to ensure that proper function and occlusion have been established. Once all of the restoration contours have been finalized all units are glazed. Contacts are checked again using a Mylar strip for consistency. Black triangles have been monitored throughout the building process and changes are made prior to final polish (Figs 31 & 32).

Final polish is an important step. A beautiful, natural luster is achieved by first rubber-wheeling the restoration until slightly dull, with particular emphasis on the high areas of the lobes or the areas of the lobes that the lips continuously rub on. Next, using a Robinson™ bristle brush (Buffalo Dental Mfg. Co.; Syosset, NY) with Dia-Shine Fine grit (VH Technologies; Bellevue, WA), polish is repeatedly worked over the restorations until the polish has disappeared (Fig 33). The veneers are steamed and ready to be devested. Devesting is a simple process using glass beads at 60 to 80 psi to blow the refractory material away from the veneer. Any overhangs or over-extensions on the margins are carefully removed using a diamond-impregnated wheel. Restorations are ready to be fit to the master dies. If the refractory work was done well, then fitting time should be minor. If there is a bit of hesitation to a restoration seating, then fit-checker spray is a handy tool. Unfortunately, refractory veneers in comparison to pressed ceramic veneers are more

fragile to fit; great care must be taken not to chip or fracture the restorations at this point. All dies are placed back into the base and the veneers are tried-in, first in small groups, adjusting any contacts necessary; and then all together to ensure that orthodontic placement is correct. A tacking material under the veneers keeps them in place during final check of occlusion and excursive movements. Veneers are transferred to the solid models to note any corrections (Fig 34). If any corrections need to be made then the d-SIGN km correction powder is applied and the units to be fired are placed on the firing tray with an instant refractory material such as Vest-It (Green-Kel Innovations Inc.; Cranberry, PA) If the program temperature is not too hot then there is very little chance of any warping. Finally, the all-on is refined with a rubber wheel and diamond-polished as before. The case is complete and the quality check is done before it is sent back to the doctor. *AF*

